

①

Feb. 8, 2018

To: Louisiana State Board of Dentistry

Subject: Improper dental practice by  
DDS Dentures & Implant Solutions,  
principal dentist, Dr. Christopher  
Haygood

1) My [redacted]-in-law, J [redacted]  
N [redacted], Shreveport, went to see  
Dr. Haygood and staff on or about  
May [redacted], 2017 about a tooth problem.  
Before [redacted] would be seen I had to  
sign a document and leave my  
American Express information on  
file saying I would be responsible  
for the bills. Although I conversed  
with 2-front office people, I never  
met Dr. Haygood or his staff.

2) J [redacted] subsequently arrived at [redacted]  
appointment, was examined, and told  
[redacted] would need to go to some other  
dentist for a root canal on the tooth.  
After that they would place a crown  
on the tooth and everything would be  
done.

2

3) They then told J [REDACTED] that in order to save time in the future they could make a mold of her tooth and send it off to a company who makes <sup>Crowns</sup> and the crown would be ready when she returned from her dental procedure by another dentist, [REDACTED], who has never had a crown or a root canal and has no "dental experience" agreed to their recommendation. A mold was made.

4) [REDACTED] then went to [REDACTED] family dentist of many years past, Dr. Steven A. Russell. Please see Exhibit A, a letter from Dr. Russell.

5) I then sent [REDACTED] to [REDACTED] Dr. William M. Hall Jr., Please see Exhibit B, a letter from Dr. Hall.

6) Dr. Hall then sent [REDACTED] to Dr. James W. Sikes Jr, please see Exhibit C, a letter from Dr. Sikes.

③

7) Subsequently, [REDACTED] returned to Dr. Sikes to have the procedure done and the tooth removed.

[REDACTED] has not yet had the implant done.

8) On the basis of above information I filed a dispute with American Express to not pay the \$880 charge from Dr. Haygood's company because of incorrect dental procedure.

Much correspondence ensued between American Express and DDS Dentures + Solutions located @ 9445 Stevens Rd., Ste. 120, Shreveport, LA 71106 - 318-686-0493.

9) After several months of "negotiation" American Express asked me if I would pay half the bill, \$440. I agreed, but DDS Dentures refused the offer. American Express said they could do no more, that they were not a law firm, and would need to process the full amount of \$880. Which they did and I paid late in 2017.

④

10) I then talked to [REDACTED] Dr. Hall, and he recommended I go to the La. Dental Association and ask for a "peer review." I did, but eventually was told a "peer review" was impossible because Dr. Haygood is not a member of the Association.

11) Going back to Dr. Hall, he recommended I call Dr. Isaac "Ike" House in Haughton, who holds some position with the Board of Dentistry. He was very forthcoming and recommended I contact you; which I did. Got your address from your staff.

What I seek from you is whatever remedy you might have to address this complaint, to alert other possible citizens, and if possible secure a refund of my \$880. We have never seen the "crown" and I am led to believe it is worthless to [REDACTED]

5

Sincerely,

R [REDACTED] N [REDACTED]

[REDACTED]

Shreveport, LA. [REDACTED]

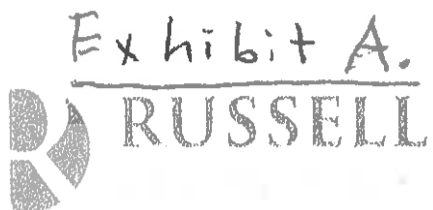
home - [REDACTED]

cell - [REDACTED]

[REDACTED]

[REDACTED]

Thank you for your  
consideration of this matter.



STEVEN A. RUSSELL, DDS

July 11, 2017

To whom it may concern,

J [REDACTED] N [REDACTED] came to our clinic for a second opinion on tooth #30 after [REDACTED] had a crown prep done at a previous dentist. The tooth had severe decay that went into the root. There was not enough tooth structure left and the tooth could not be saved. We recommended that [REDACTED] have the tooth extracted and an implant placed.

Thank you,



Dr. Steven A. Russell

Exhibit B

William M. Hall Jr., D.D.S.  
3100 Woodlawn Avenue  
Shreveport, Louisiana 71104  
(318) 865-1469 Phone (318) 868-8212 Fax

July 11, 2017

To whom it may concern:

Ms. J [REDACTED] N [REDACTED] presented to my office on June [REDACTED] 2017, requesting treatment recommendations for tooth #30.

[REDACTED] reported that [REDACTED] was currently having this tooth treated, in another office, and that there, the treating dentist had prepared [REDACTED] deeply decayed tooth for a crown and then referred [REDACTED] out-of-office for a root canal treatment to be completed before delivery of the prosthetic crown. Seeking to have the recommended root canal treatment performed, the doctor of [REDACTED] choice expressed surprise to [REDACTED] that the root canal had not been completed, as is the accepted sequence of treatment, before the crown preparation had been done.

[REDACTED] N [REDACTED] asked my therapeutic recommendations.

A periapical radiograph was taken, which showed the tooth had, indeed, been prepared for a crown and had an unusual-appearing temporary crown in place on it. Something in excess of one half of the normally existing tooth structure has been lost to decay and the crown preparation procedures. One of the lower margins (edges) of the crown preparation appears to be down to the level of the bone that supports the tooth. The extent of the tooth loss comes very close to the internal chamber which encloses the nerve tissues of the tooth.

These conditions would mitigate against attempting a conventional crown without first considering root canal therapy, crestal bone removal and periodontal recontouring procedures. These procedures, designed to improve the chances for a successful placement of a conventional prosthetic crown, need to be completed, successfully, prior to attempting a crown preparation.

In my opinion, to proceed with root canal therapy and the placement of a prosthetic crown (the impression for which has already been taken), absent the prior successful completion of these preparatory procedures, is unlikely to lead to a good prognosis for the tooth, or its surrounding gum and bone.

The challenge and expense of these having these "support procedures" successfully performed, and the fact that the tooth would lose additional natural structure during the efforts, leads to my opinion, that I would not have recommended a conventional prosthetic crown at all, but would recommend extraction and placement of an implant to support a prosthetic crown.

  
William M. Hall, Jr., D.D.S.

bit C



HIGHLAND CLINIC

J.W. SIKES, JR., DMD, MD  
ORAL & MAXILLOFACIAL SURGERY

2017

in it may concern,

██████ N ██████

On ██████ 2017 ██████ was seen for consultation and we discussed the pathology and prognosis of tooth ██████. In my medical opinion that the tooth has poor long term prognosis and would best be treated with extraction and restoration with an implant supported fixed partial denture.

Thank you for the referral and please contact me if you have any further questions or concerns.

Sincerely,

J.W. Sikes Jr. DMD, MD